

Conditions for Rejection of Poultry at Post Mortem

Cellulitis

Post-mortem Disposition

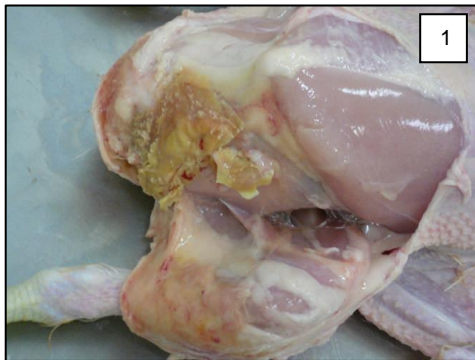

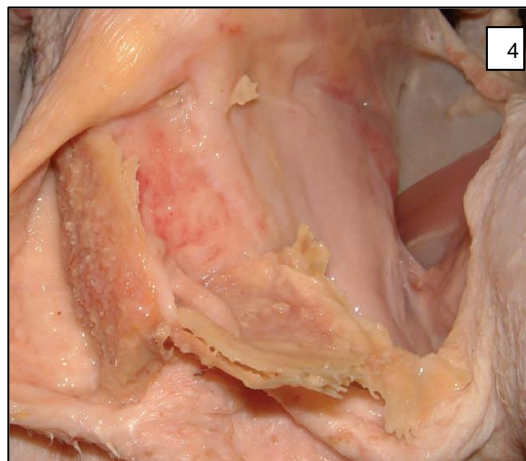
Figure 1: Skin reflected to reveal pus plaque and inflammation.

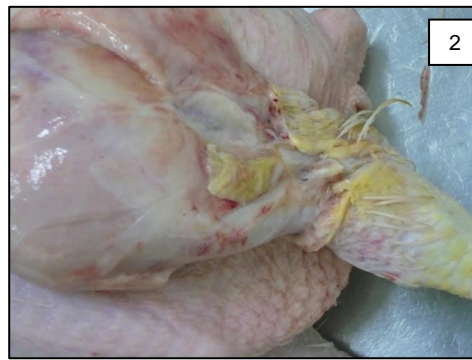

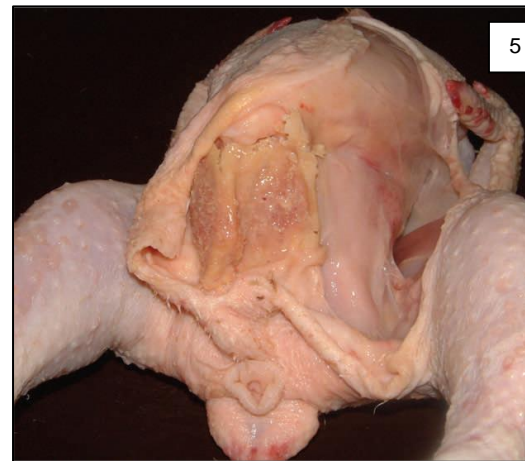
Figure 2: Skin removed.

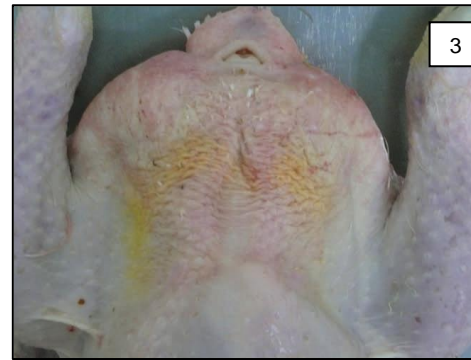

Figure 3: Bilateral cellulitis lesion in the vent area.



Figures 4 & 5: Showing a dry form of cellulitis. These lesions tend to be sterile. Affected parts can be trimmed and the rest of the carcass salvaged.



FSS Responsibilities

Post-mortem disposition

Partial rejection should be considered if lesions are localised, systemic effects are not observed and provided that the trimming is carried out in a way which is acceptable to the OV.

Total rejection is required if cellulitis lesions are not clearly localised or are accompanied with systemic effects.

Recording of the condition

The condition must be recorded as "Cellulitis" in the Post-Mortem Inspection module of OWS.

Further Information

Definition

Cellulitis is an inflammation of the connective tissue between the skin and muscle caused by infection.

Remarks

It is commonly found beneath the abdominal skin in the region of the navel and the upper thighs in broilers. Affected birds are only detectable after slaughter, once the carcass has been scalded and plucked. The condition presents as a yellowing and thickening of the subcutaneous connective tissue which when incised may reveal the seropurulent lesion or plaque of inspissated pus.

Causes

1. Physical trauma such as scratches that lead to secondary bacterial infection.
2. Immunosuppressive diseases such as Gumboro disease.

The bacteria involved is usually E.coli.

How is this information used?

Incidence of cellulitis may be associated with some type of management deficiency on the farm and will allow the company to target such farms in order to resolve the issues.

Private veterinarians can rule out immunosuppressive conditions such as Gumboro disease.

Acknowledgements to:

Pablo Hervas (OV) and British Veterinary Poultry Association for the development of the condition card

Pictures: Pablo Hervas (OV), Asier Pagazaurtundua (VM),